



# YOUR SURGICAL CONSULTANT

Available 24 hours daily at:

**(817) 336-7881**

Fax: (817) 336-6821

---

## Southwest Office

7100 Oakmont, Suite 201-B  
Fort Worth, TX 76132

Office hours: 1 to 5 pm M-W-F

## Downtown Office

901 7<sup>th</sup> Avenue, Suite 210  
Fort Worth, TX 76104

Office hours: 8 am to 5 pm weekdays

## Grapevine Office

2020 W Hwy 114, Suite 110  
Grapevine, TX 76051

Office hours: 1 to 5 pm Tu  
9 am to noon Th

---

**September 2007**

<http://www.pedisurgdfw.com>

**Volume 2, Number 9**

---

Your patients deserve consistent care from experienced surgeons who are Board Certified in Pediatric Surgery. Regardless of which PSA surgeon is on call, or which one is rounding on the group's patients that day, you will find little variation in expertise among the four of us; we have the most total years of surgical experience, and most importantly, each of us is Board Certified in Pediatric Surgery.

---

## GASTROESOPHAGEAL REFLUX DISEASE

Gastroesophageal reflux (GER) is the regurgitation of gastric contents into the esophagus. About one-third of the roughly 8 million babies born annually in the US will have GER during the first months of life; the great majority of these infants will resolve the reflux by their first birthday. Infants with serious symptoms or children with continuing symptoms of GER have gastroesophageal reflux disease (GERD) and should be treated to eliminate both the associated symptoms and the complications.

### Symptoms

Symptoms of GERD in children are numerous but vary between patients. Crying, refusing food, lack of weight gain, or chest pain in older children might be signs of acid irritation of the esophagus. Halitosis, belching, or effortless regurgitation could indicate the presence of gastric contents within the esophagus. Cyanotic episodes, coughing, voice changes, recurrent pneumonia, or reactive airways disease may indicate aspiration of refluxed gastric contents onto or through the vocal cords. Chronically poor dentition or frequent episodes of otitis media or sinusitis can indicate regurgitation of gastric contents into the mouth or nasopharynx during sleep. Chronic GERD may result in the development of metaplasia of the distal esophageal mucosa, i.e., a change from squamous to columnar epithelium (Barrett's esophagus). This occurs in about 10% of all patients seeking treatment for symptomatic GERD. Barrett's esophagus is a premalignant condition. The risk of developing adenocarcinoma of the esophagus with this condition is low—about 0.5%—but this is still 30 to 125 times the usual risk.

The presence of a hiatus hernia is a risk factor for developing GER but does not necessarily indicate that GERD is present. Formula-fed infants are more likely to reflux than breast-fed. Infants 'burped' frequently when feeding are less likely to reflux. Overfed infants are predisposed to reflux.

### Diagnosis

Useful diagnostic studies include upper GI radiography (UGI), reflux sonography (RS), esophageal pH monitoring, esophageal impedance monitoring (IM), and esophagogastroscopy (EGD). The UGI and RS can each detect about 80% of cases of GERD; but because these tests are not mutually inclusive, about 10% of cases will still be undetected. A pH study is the most accurate test for acid reflux but it must be performed after the child has been off of antacid medications for several days, and it usually requires general anesthesia to ensure proper probe placement. IM is not pH-dependent, and a combined pH/IM study may become the "gold standard" for diagnosing GERD. EGD is not as helpful in the diagnosis of GERD as it is in assessing the effects of GERD such as chronic inflammatory changes, or, in older patients with long-standing disease, Barrett's esophagus.

### Etiology

A complex interaction between the anatomy of the area and muscle activity normally results in a functional 'one-way valve' at the gastroesophageal junction. The angle between the stomach and the esophagus entering the stomach (the angle of His) is of particular importance in preventing GER; when a cadaver stomach with an intact angle of His is filled with water, it will usually rupture before reflux occurs.

---

W. Glaze Vaughan, MD

David P. Bliss, Jr., MD

• C. Thomas Black, MD

• José L. Iglesias, MD

---

**Treatment options**

The treatment of GER in infants and children includes non-medicinal, pharmaceutical, and surgical methods.

Non-medicinal methods include thickening of infant formulas with rice cereal or with modified cornstarch (e.g., Thick-It®), positioning the child on his stomach or left side, and elevating the head of the bed. Although food and even water may be artificially thickened, prepared thickened formulas such as Enfamil AR (Added Rice) are also available.

Medications effective in treating GERD include **proton pump inhibitors** (esomeprazole [Nexium®], lansoprazole [Prevacid®], omeprazole [Prilosec®], pantoprazole [Protonix®], rabeprazole [Aciphex®]); **antacids** (Maalox®, Mylanta®, Riopan®, Roloids®, Tums®); **H<sub>2</sub> receptor blockers** (cimetidine [Tagamet®], famotidine [Pepcid®], ranitidine [Zantac®]); and **prokinetics** (metoclopramide [Reglan®], cisapride [Propulsid®, no longer available in the US], bethanechol). Practically speaking, the first three classes of medications are aimed at reducing only the *acid-related effects* of GERD, not the GER itself, while prokinetics alone promote prograde esophageal motility and gastric emptying.

Surgical treatment of GERD is reserved for those who fail medical management or have significant complications. The ‘gold standard’ is the fundoplication; the Nissen version is the most frequently performed, although the Thal and Toupet varieties are preferred by some surgeons.

**We commonly perform the Nissen fundoplication laparoscopically.** In the Nissen procedure, the fundus of the stomach is passed behind the distal esophagus (Figure 1), wrapped 360°, and sutured (plicated) to itself anteriorly (Figure 2). While the procedure is highly effective at preventing GER, the mechanism is unclear. Restoring the angle of His, applying pressure on the distal esophagus, placing the distal 2 cm of the esophagus within the abdomen, and repairing any hiatal hernia present may each contribute to the approximately 90% success rate of the procedure. Complications include making the wrap too tight (may cause

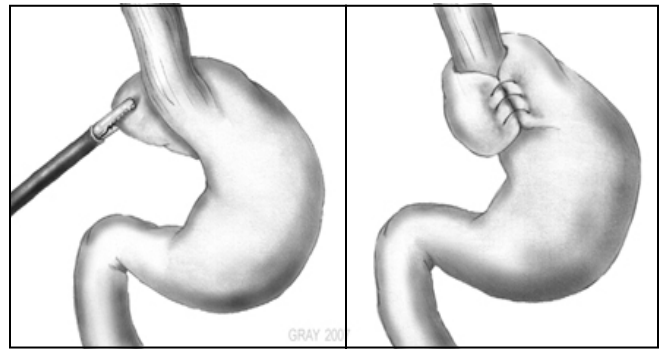


Figure 1

Figure 2

future difficulty in swallowing), making the wrap too loose (may allow mild residual GER), or dehiscence of the plication (a 5-10% risk, which causes a return to preoperative GER). About one-third of all children who undergo a Nissen fundoplication will experience gagging or retching, but this usually resolves spontaneously within a few months.

In the Thal procedure, the fundus of the stomach is wrapped *anteriorly*, and only 270° rather than 360°. In the Toupet procedure, the wrap is *posterior* and 180°. Both of these latter procedures have a lower risk of dysphagia, but both also carry a higher risk of post-operative GER.

Four procedures have gained approval by the FDA for the endoscopic treatment of GERD in adults—the Endocinch™, the Stretta® procedure, the NDO Surgical Plicator™, and the Enteryx®. The Endocinch™ places sutures at the GE junction, gathering the tissue into pleats and tightening the junction. In the Stretta® procedure, a probe is positioned at the GE junction and high-frequency radio waves are emitted. The radio waves induce the development of scar tissue which tightens the junction. The Plicator™ is similar to the Endocinch™ but has been recalled. The Enteryx® procedure involved injection of a polymer into the GE junction, but this was removed from the market by the FDA due to complications. The long-term efficacy of each method is undetermined, and none are approved yet for use in children.

# SEPTEMBER

Sunday	Monday	Tuesday	Wednesday	Thursday	Friday	Saturday
<b>30</b> José Iglesias	We are available 24 hours every day. Please page directly to the number listed for direct referrals or for an immediate consultation.					<b>1</b> Tom Black
<b>2</b> José Iglesias	<b>3</b> Tom Black	<b>4</b> David Bliss	<b>5</b> Glaze Vaughan	<b>6</b> José Iglesias	<b>7</b> David Bliss	<b>8</b> Glaze Vaughan
<b>9</b> David Bliss	<b>10</b> Tom Black	<b>11</b> Glaze Vaughan	<b>12</b> José Iglesias	<b>13</b> David Bliss	<b>14</b> Glaze Vaughan	<b>15</b> Tom Black
<b>16</b> Glaze Vaughan	<b>17</b> José Iglesias	<b>18</b> Glaze Vaughan	<b>19</b> Tom Black	<b>20</b> José Iglesias	<b>21</b> David Bliss	<b>22</b> José Iglesias
<b>23</b> David Bliss	<b>24</b> José Iglesias	<b>25</b> David Bliss	<b>26</b> Tom Black	<b>27</b> Glaze Vaughan	<b>28</b> José Iglesias	<b>29</b> David Bliss

**Disclaimer:** All material is intended for informational purposes only and is not intended, and should not be used, to replace medical advice offered by a qualified physician. We are always available and willing to discuss questionable conditions with you and we invite your request for our assistance.